Oxygen-Enhanced MRI (OE-MRI) In a Heterotopic Syngeneic Murine Model of Non-Small Cell Lung Cancer (NSCLC) Treated with Radiation Therapy (RT) and L-Carnosine.

Vansh Sandhu[1], Jorge Campos Pazmiño[1], Ives Levesque[1,2], Norma Ybarra[1,2]
[1]Medical Physics Unit, McGill University
[2]Research Institute of the McGill University Health Centre

McGill University
Centre universitaire de santé McGill Institut de recherche
McGill University Health Centre Research Institute
2026 JULY 19–22 VANCOUVER, BC
JOINT AAPM | COMP MEETING

ABSTRACT

Purpose: Oxygen-enhanced (OE) and BOLD MRI provide metrics of oxygenation through R_1 and R_2^*, respectively. This study investigated multiparametric MR-oximetry to detect radiotherapy (RT) related differences in tumour oxygenation in a heterotopic syngeneic Lewis lung carcinoma murine model.

Methods: Sixteen mice were assigned to control (Ctrl, n=3), RT only (RTo, n=5), or RT with L-carnosine (CarRT, n=6) groups. An eight Gy RT fraction was delivered three days before imaging at 7 T. ΔR_1 and ΔR_2^* (O_2 - air) from the difference between data collected with the animals breathing medical air and 100% oxygen were analysed using linear mixed-effects models. Immunohistochemical analysis of CD31 and GLUT1 provided vascular density and metabolic adaption markers, respectively.

Results: ΔR_1 was positive within all groups and significantly greater in RT groups relative to control, indicating that RT altered tumour tissue oxygenation. ΔR_2^* was negative in control and CarRT, suggesting an increase in blood oxygenation under hyperoxic challenge, but was not significantly different from zero in RTo and was significantly less negative in RTo than control, indicating a reduced vascular response to oxygen. CD31 expression was significantly lower in RTo compared to control, suggesting RT-induced reductions in microvessel density, while no significant CD31 difference was observed between CarRT and control. GLUT1 expression showed no significant variations.

Conclusion: MR-oximetry is sensitive to treatment associated alterations in both tissue oxygenation and vascular structure in this NSCLC model. ΔR_1 differences between groups were consistent with a tissue oxygenation response, whereas reduced ΔR_2^* response in RTo appears to be driven partially by reduced microvessel density rather than blood oxygenation alone.

CONTACT

Vansh Sandhu
McGill University

vansh.sandhu@mail.mcgill.ca
604-226-7914

INTRODUCTION

Lung cancer is a leading cause of cancer-related mortality worldwide, with NSCLC comprising 85-90% of cases[1]. Radiotherapy is integral to NSCLC management; however, radiotherapy's effectiveness depends on tumour oxygenation[2]. Hypoxia occurs in 50-80% of NSCLC tumours and predicts poor prognosis[3]. Oxygen-enhanced MRI (OE-MRI) combined with BOLD MRI offers a promising, repeatable, non-invasive method of hypoxia tracking that uses the paramagnetic properties of dissolved oxygen during oxygen breathing to detect hypoxia without ionizing radiation[4,5].

This study investigated multiparametric MR-oximetry, using ΔR_1 and ΔR_2^* (O_2 - air), as a method to detect treatment-related differences in tumour oxygenation in a heterotopic syngeneic Lewis lung carcinoma murine model comparing control, RT-only, and RT combined with L-carnosine groups. MR-oximetry measurements were complemented by immunohistochemical (IHC) analysis using CD31 and GLUT1 to compare imaging findings with markers of microvessel density and hypoxia-related metabolic adaptation, respectively.

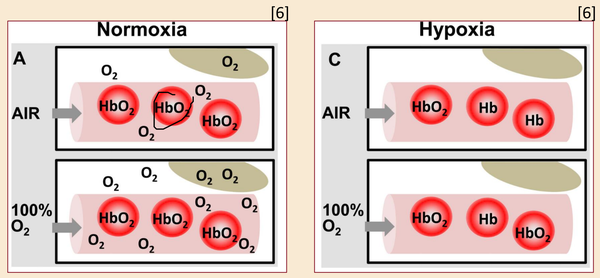

Measurements of interest

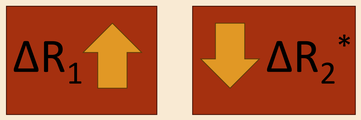

METHODS AND MATERIALS

A subcutaneous syngeneic NSCLC tumour model was used. 16 m\ice were distributed into 3 categories: control (Ctrl, n=3), carnosine injections with radiotherapy (CarRT, n=6), and saline injections with radiotherapy (RTo, n=5). Imaging protocol included:

- T_2-weighted rapid acquisition with refocused echoes (RARE) scan (8min 17s)
- Multi-echo gradient echo (MGE) scan (9min 4s)
- T_1-weighted RARE with variable repetition times (RARE-VTR) (12min 33s)

Data from maps of R_1 ($1/T_1$) and R_2^* ($1/T_2^*$) was analysed with linear mixed-effects models (LME). Resected tumours were sent for immunohistochemistry to detect hypoxia and vascular markers.

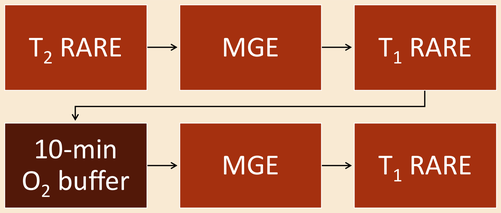

RESULTS

LME modeling of R_1 revealed significant effects of oxygen breathing and of treatment group. R_1 under air breathing did not differ significantly across the treatment groups. ΔR_1 was greater in both RTo and CarRT groups relative to Ctrl (+0.012, $p < 0.01$ and +0.008, $p = 0.03$, respectively), suggesting a treatment-associated alteration in tissue oxygenation.

ΔR_2^* varied significantly between RTo and Ctrl ($p < 0.01$). ΔR_2^* was significantly less negative in RTo relative to Ctrl (+1.64, $p < 0.01$), while ΔR_2^* in CarRT did not differ significantly from Ctrl ($p = 0.20$).

GLUT1 expression was higher in RT treatment groups, however, there was no significant difference between any groups.

CD31 expression was lower in both RT treatment groups compared to control and there was a significant difference between Ctrl and RTo groups ($p = 0.03$).

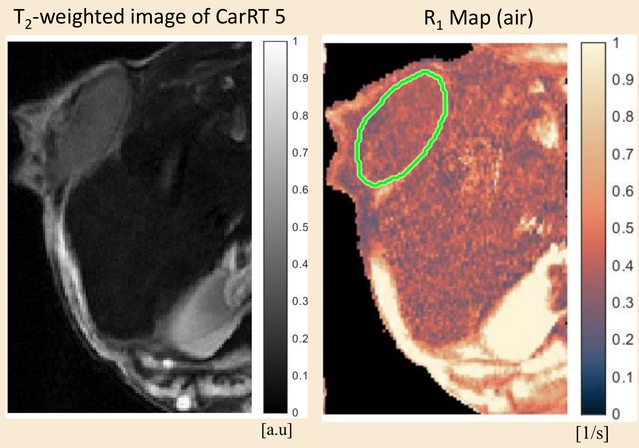

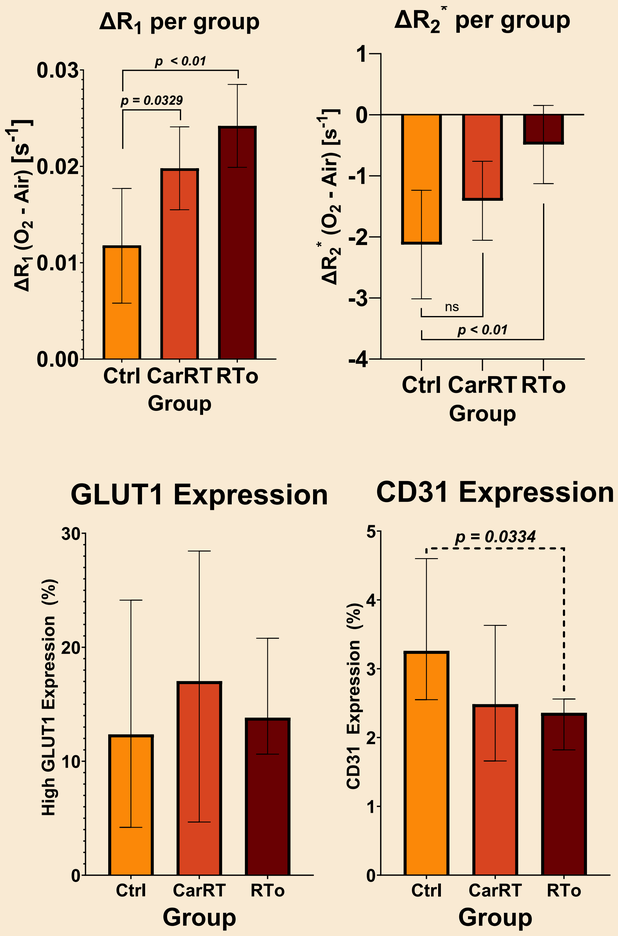

DISCUSSION

ΔR_1 showed significant increases from control to both RT groups, suggesting that this metric is sensitive to treatment related oxygenation changes in this tumour model. The ΔR_1 differences between groups are consistent with an oxygenation response, in line with the established interpretation of ΔR_1 as a marker of dissolved oxygen in tissue.

ΔR_2^* also revealed significant differences between the control and radiotherapy only groups and no significant difference between control and carnosine with radiotherapy.

Vascular density, as assessed by CD31, was significantly reduced from the control group to the radiotherapy only group, this finding combined with the observed ΔR_2^* change between Ctrl and RTo suggests that ΔR2* differences between groups likely reflect functional alterations, such as changes in vascular geometry or volume.

Lastly, the trend toward elevated GLUT1 expression in treated tumours suggests that tumour cells may maintain a metabolically adapted phenotype despite tissue and vascular oxygenation changes. Taken together, these results support a dissociation between tumour oxygen handling and tumour metabolic state, suggesting that changes in tissue or vascular oxygen response do not necessarily translate into reduced glycolytic dependence or reversal of the stress-adapted phenotype of cancer cells.

CONCLUSIONS

This study demonstrated that MR-oximetry with an oxygen challenge can detect treatment-associated alterations in tumour tissue oxygenation and vascular structure, as evidenced by differences in ΔR_1, ΔR_2^*, and CD31 in RT treated tumours compared to untreated tumours.

REFERENCES

1. Molina JR, et al. Non-small cell lung cancer: epidemiology, risk factors, treatment, and survivorship. *Mayo Clin Proc.* 2008;83:584-94.
2. Hill RP. Hypoxia and predicting radiation response. *Semin Radiat Oncol.* 2015;25:187-91.
3. Vaupel P, Mayer A. Hypoxia in cancer: significance and impact on clinical outcome. *Cancer Metastasis Rev.* 2007;26:225-39.
4. O'Connor JPB, Robinson SP. Imaging tumour hypoxia with oxygen-enhanced MRI and BOLD MRI. *Br J Radiol.* 2019;92:20180662.
5. Little RA, et al. Mapping Hypoxia in Renal Carcinoma with Oxygen-enhanced MRI. *Radiology.* 2018;288:739-47.
6. O'Connor JPB, Boult JKR, Jamin Y, et al. Oxygen-Enhanced MRI Accurately Identifies, Quantifies, and Maps Tumor Hypoxia in Preclinical Cancer Models. *Cancer Res.* 2016;76(4):787-795. doi:10.1158/0008-5472.CAN-15-2062

© Poster Template by Genigraphics® 1.800.790.4001 www.genigraphics.com