2026 JULY 19–22 VANCOUVER, BC
JOINT AAPM | COMP MEETING

Predictive value of synthetic PET imaging for assessing biology-guided radiotherapy feasibility: results from a prospective imaging study

Chunhui Han[1], Sagus Sampath[1], Sean Maroongroge[1], Savita Dandapani[1], Jose Bazan[1], Arya Amini[1], Sean Szeja[1], An Liu[1], Jeffrey Wong[1]
[1]Department of Radiation Oncology, City of Hope National Medical Center, Duarte, California, USA

ABSTRACT

Purpose/Objective(s): To evaluate the ability of synthetic PET images derived from standard-of-care (SOC) 18F-FDG PET/CT images to predict the feasibility of biology-guided radiotherapy (BgRT).
Materials/Methods: In this prospective imaging study, patients undergoing SOC 18F-FDG PET/CT subsequently received a PET scan on a BgRT platform (X1). Disease sites include the head & neck region, esophagus, mediastinum, abdomen, and pelvis. Gross target volumes (GTVs) were delineated on SOC PET/CT images for PET-avid lesion. Planning target volumes (PTVs) were defined as 5-mm isotropic expansions of the GTV, and biology tracking zones (BTZs) were defined as 5-mm isotropic expansions of the PTV. Synthetic PET images were generated from SOC PET images to simulate predicted PET Images acquired on the BgRT machine. BgRT treatment planning was attempted on both synthetic PET and X1 PET images. Activity concentration (AC) and normalized target strength (NTS) were assessed to determine BgRT feasibility.
Results: X1 PET scan were performed with an average of 2.0±0.6 hours (range: 1.3 - 3.2 hours) after SOC PET/CT imaging. Of the 17 patients who completed both SOC PET/CT and X1 PET scans, BgRT planning based on synthetic PET images were successful for 13 patients, whereas BgRT planning based on X1 PET images was successful in 9 patients. Among the 8 cases in which X1 PET-based planning failed, 4 also failed synthetic PET-based BgRT planning. Three cases passed synthetic PET-based planning but were correctly predicted to fail X1 PET-based BgRT planning due to reduced AC from decay, and one case failed X1 PET-based planning due to lower-than-predicted AC relative to SOC PET.
Conclusion: These results demonstrate the clinical utility of synthetic PET imaging for BgRT planning. Feasibility outcomes derived from synthetic PET images were predictive of BgRT planning success on actual X1 PET images in the majority of cases.

Chunhui Han
City of Hope
1500 E Duarte Rd, Duarte, CA 91010
chan@coh.org
+1 626-218-5174

INTRODUCTION

Biology-guided radiotherapy (BgRT) leverages real-time PET signals to localize and steer radiation delivery toward metabolically active tumors. The RefleXion X1 machine (RefleXion Medical, Inc., Hayward, California) integrates a PET imaging subsystem onto its ring gantry, allowing for real-time PET-guided beam modulation in BgRT treatments.

At present, a patient being considered for BgRT requires functional-modeling PET imaging on the X1 over the target region before BgRT treatment can be planned. This requirement creates a practical workflow challenge as patients may undergo additional scanner time and setup before it is known whether the lesion will satisfy BgRT feasibility criteria. The ability to predict whether a given lesion will meet BGRT feasibility thresholds before the FM PET scan is critical to clinical workflow and resource utilization. The aim of this study is to evaluate the ability of synthetic PET images derived from diagnostic PET/CT images to predict BgRT feasibility.

METHODS AND MATERIALS

In a recently completed prospective imaging study [1], patients undergoing SOC 18F-FDG PET/CT for non-bone and non-lung lesions subsequently received a PET scan on the X1. Seventeen patients completed both scans and formed the cohort for primary analysis. Lesion sites included head and neck regions, esophagus, mediastinum, abdomen, pelvis, chest wall/pleural region, and scalp. Gross target volumes (GTVs) were delineated on SOC PET/CT images for FDG-avid lesions. Planning target volumes (PTVs) were defined as 5-mm isotropic expansions of the GTV, and biology tracking zones (BTZs) were defined as 5-mm isotropic expansions of the PTV.

Synthetic PET images were generated from SOC PET images to simulate predicted PET Images acquired on the BgRT machine. BgRT treatment planning was attempted on both synthetic PET and X1 PET images. Activity concentration (AC) and normalized target strength (NTS), as well as other PET operational metrics, were assessed to determine BgRT feasibility. The same feasibility thresholds were prespecified as AC ≥ 5 kBq/mL and NTS ≥ 2.7 to ensure sufficient tumor signal for real-time PET guidance. Figure 1 shows the schematic of this study.

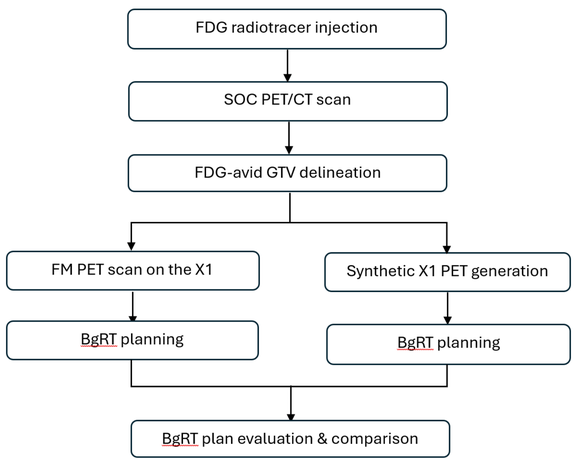

Figure 1: schematic of this study.

RESULTS

For the seventeen evaluable patients, mean age was 60 ± 12 years (range, 40–90 years). The cohort included 10 male and 7 female patients. Mean weight was 82.7 ± 15.1 kg (range, 63.0–123.7 kg), mean injected FDG activity was 11.3 ± 2.6 mCi (range, 7.3–15.6 mCi), and the mean SOC PET/CT-to-X1 PET interval was 2.0 ± 0.6 hours (range, 1.3–3.2 hours). Figure 2 shows representative synthetic and X1 PET images in this study.

BgRT planning based on synthetic PET images were successful for 13 patients. Among the four patients with infeasible synthetic PET-based BgRT planning, two were infeasible because AC was below the 5 kBq/mL threshold, one because NTS was below the 2.7 threshold, and one because a PET operating parameter failed to meet an internal operating threshold.

BgRT planning based on X1 PET images was successful in 9 patients. All the eight patients with infeasible X1 PET-based BgRT planning failed because the AC was below the 5 kBq/mL threshold. Among the eight cases in which X1 PET-based planning failed, four also failed synthetic PET-based BgRT planning. Three cases passed synthetic PET-based planning but were correctly predicted to fail X1 PET-based BgRT planning due to reduced AC from decay, and one case failed X1 PET-based planning due to lower-than-predicted AC relative to SOC PET.

Figure 3 compares decay-adjusted synthetic PET AC versus X1 PET AC in 15 of the 17 patients. Two patients were not included in Figure 2 because the X1 TPS did not generate AC values due to planning failure for other reasons discussed above. The average difference between the synthetic PET-predicted AC and the X1 PET AC was 0.58 ± 4.12 kBq/mL (range: -7.50–10.92 kBq/mL).

For successful BgRT plans based on X1 PET imaging, the mean GTV volume was 18.3 ± 13.6 cm³, and the mean PTV volume was 46.9 ± 25.2 cm³. Mean AC was 10.2 ± 2.9 kBq/mL, and mean NTS was 9.7 ± 5.4. Mean estimated beam-on time was 29.5 ± 7.8 minutes. The mean conformity index was 1.42 ± 0.22, and the mean heterogeneity index was 1.46 ± 0.28.

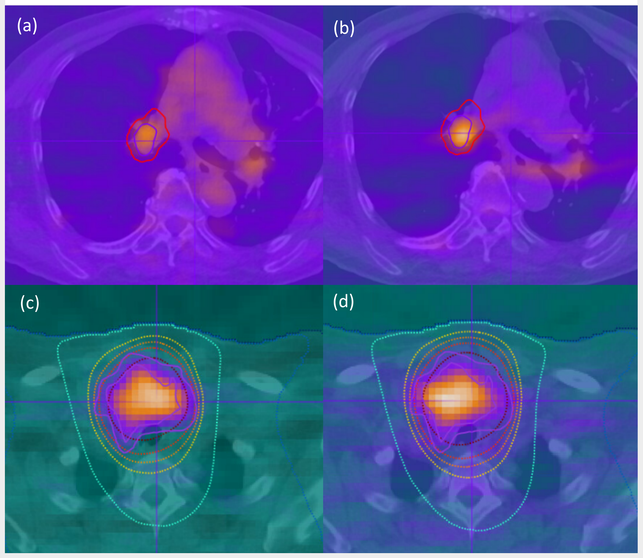

Figure 2: Comparison of synthetic PET images (a & b) derived from SOC PET and X1 PET images (b and d) for (top) a mediastinal and (bottom) a lower neck lesion in this study. In each pane, The PET image is overlaid on the SOC CT image.

DISCUSSION

A notable strength of this work is its prospective design and direct paired comparison between synthetic PET-based assessment and subsequent X1 PET-based planning in the same patients. The study also uses clinically relevant thresholds directly tied to X1 BgRT planning. Synthetic PET–based planning overestimated X1 feasibility in some patients when evaluated without accounting for decay; however, decay-adjusted assessment explained most discordant cases. After incorporating decay-aware AC evaluation, synthetic PET results were clinically concordant with X1 PET feasibility outcomes in most patients. These findings support synthetic PET as a practical pre-scan triage tool and emphasize the importance of imaging timing in X1 functional-modeling (FM) PET workflows.

The clinical relevance of these findings is primarily workflow related. FM PET acquisition on the X1 requires imaging-only plan generation, patient setup, and a relatively long PET acquisition. If synthetic PET derived from SOC PET/CT can identify lesions unlikely to meet AC or NTS requirements, patients and care teams may be able to avoid unnecessary FM PET imaging on the X1, thereby improving resource utilization and streamlining patient selection for BgRT evaluation.

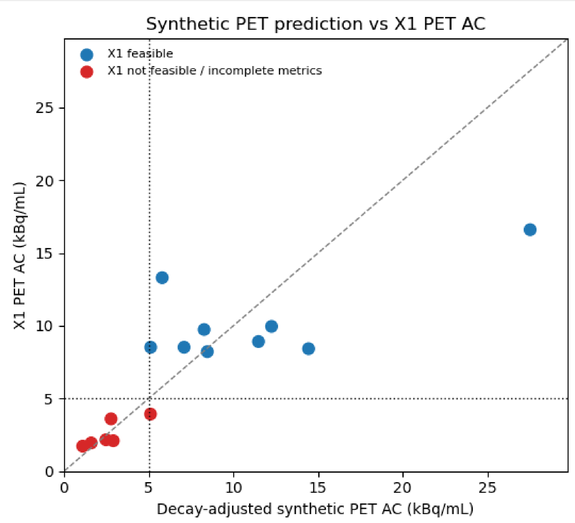

Figure 3. Decay-adjusted synthetic PET AC versus X1 PET AC. Dotted lines indicate the 5 kBq/mL AC threshold; the dashed diagonal indicates equality.

CONCLUSIONS

These results demonstrate the clinical utility of synthetic PET imaging for BgRT planning. Feasibility outcomes derived from synthetic PET images were predictive of BgRT planning success on actual X1 PET images in the majority of cases.

REFERENCES

1. Han C, Sampath S, Maroongroge S, et al. A Prospective Pilot Study of [18F]-FDG Imaging with the PET-CT Subsystem on a Biology-Guided Radiotherapy Machine. Int J Radiat Oncol Biol Phys 2025;123(suppl):S251. DOI: 10.1016/j.ijrobp.2025.07.1397.

© Poster Template by Genigraphics® 1.800.790.4001 www.genigraphics.com