Characterization of Delayed Imaging Quantitative Accuracy on a Long Axial Field-of-View/Total-Body PET Scanner

Azeez A Omotayo, PhD[1]; Alexander Rice, PhD[2]; Jennifer L Bartels PhD[3]; Amy L Vavere, PhD[1]
[1]Department of Radiology, St Jude Children's Research Hospital, Memphis USA, [2]United Imaging Healthcare North America, Houston USA, [3]United Imaging Healthcare North America, Houston USA

2026 JULY 19–22 VANCOUVER, BC
JOINT AAPM | COMP MEETING

ABSTRACT

Purpose:
To quantify radiotracer- and reconstruction-dependent feasibility of delayed PET imaging on a long axial field-of-view (LAFOV) system, and to identify pediatric-relevant delayed imaging windows (or equivalent low-activity protocols) while maintaining small-lesion quantitative performance.

Methods:
A NEMA NU-2 image quality phantom (six spheres: 10–37 mm) was imaged using six PET radiotracers (F-18, C-11, N-13, Ga-68, Cu-64 and Zr-89) with 30-min acquisitions at serial delays through 10 half-lives (analysis at HL1/2/4/6/8/10). Reconstructions included TOF+PSF using OSEM (3 iterations, 10 subsets, no post-filter), vendor-provided Hyper-Iterative (HI), and Deep Progressive Reconstruction (DPR). Metrics included target-to-background ratio (TBR),contrast recovery coefficient (CRC), background variability (BV%), lesion variability (LV%), and contrast-to-noise ratio (CNR). Uncertainty-based 95% confidence intervals (CI) for TBR and CRC were computed by error propagation.

Results:
Small spheres (10–13 mm) governed feasibility. Under a balanced pediatric decision rule (CRC lower 95% CI ≥0 .70, BV% ≤ 25, and size-dependent CNR thresholds), maximum feasible delays for 10–13 mm targets were: C-11 up to HL4(HI), N-13 up to HL6 (HI), Ga-68 up to HL6 (DPR), F-18 up to HL8 (HI), and Cu-64 up to HL4 (OSEM). These correspond to remaining activity fractions of 1/16, 1/64, 1/64,1/256, and 1/16, respectively.

Conclusion:
LAFOV PET enables extended delayed (low-count) imaging windows that are tracer- and reconstruction-dependent. Uncertainty-based constraints support conservative pediatric protocol optimization and provide objective bounds for activity reduction while preserving small-lesion quantitative performance.

Azeez Omotayo
St Jude Children's Research Hospital
262 Danny Thomas Pl, Memphis, TN 38105
azeez.omotayo@stjude.org
+1 901-595-3927

INTRODUCTION

Long axial field-of-view (LAFOV) and Total-Body PET systems increase geometric acceptance and effective sensitivity [1, 2] by scanning and covering a substantially larger fraction of the patient or phantom simultaneously

Delayed imaging – scanning at least one half-life interval/delay after injection – capitalizes on the physiological clearance of unbound tracers from healthy tissues and blood pools, while retention in target-specific lesions continues during and post-delay. This temporal mismatch naturally enhances contrast-to-noise ratio (CNR) and tumor-to-background ratio (TBR).

Because delayed imaging is fundamentally count-limited, physical decay, positron branching fraction, positron energy, and positron range all influence image formation.

Rationale: LAFOV or Total-Body PET scanners offer much improved scan efficiency, and might be especially beneficial for pediatrics

Objectives:
1. Evaluate the quantitative accuracy of delayed scans across multiple PET tracers/nuclides
2. Determine the optimal delayed imaging windows for clinical protocols using the NEMA IQ and mini-Derenzo phantoms
3. Evaluate feasibility of delayed scans in pediatric patients (pending)

Scanner: uMI Panorama-GS PET-CT (United Imaging Healthcare, Houston USA)

Phantoms:
1. NEMA NU-2 (for IQ metrics)
2. mini-Derenzo (for small lesion resolution)

Radionuclides: N-13, C-11, Ga-68, F-18, Cu-64, Zr-89

Metrics: Recovery Coefficient (RC), Contrast Recovery (CRC), Target-to-Background Ratio (TBR), Contrast-to-Noise Ratio (CNR), Background-noise Variability (BV), Detectability index (DI)

Imaging intervals/windows: The intended sphere-to-background activity concentration ratio was approximately 4:1. Serial PET acquisitions (@ 30min per scan) were obtained at nominal half-life intervals (HL0, HL1, HL2, and subsequent intervals through approximately HL10)

Figure 1. uMI 148cm LAFOV Panorama-GS PET/CT



Figure 2. NEMA NU-2 phantom

RESULTS

Figure 3 shows the NEMA IQ phantom delayed scan images from HL1 – HL8. Figure 4A shows that the absolute TBR and CRC values were comparatively preserved across moderate count reductions, whereas absolute CNR decreased and BV% increased monotonically with decay, as shown in Figure 4B. This indicates that delayed imaging primarily fails through loss of statistical count detectability rather than through a proportional loss of mean contrast recovery.



Figure 3: NEMA NU-2 IQ phantom images for the six different PET radionuclides (N-13, C-11, F-18, Cu-64, Ga-68, Zr-89) at delayed count fractions of 1/2 (HL1), 1/4 (HL2), 1/16 (HL4) and 1/256 (HL8) of the injected activity (6.83 mCi, 10.51 mCi, 4.32 mCi, 2.01 mCi, 2.99 mCi, and 2.8 mCi, respectively). OSEM-reconstruction was applied for each image, using 3 subsets and 10 iterations with PSF+TOF corrections. Voxel size is 1.5×1.5×2.0 mm^3

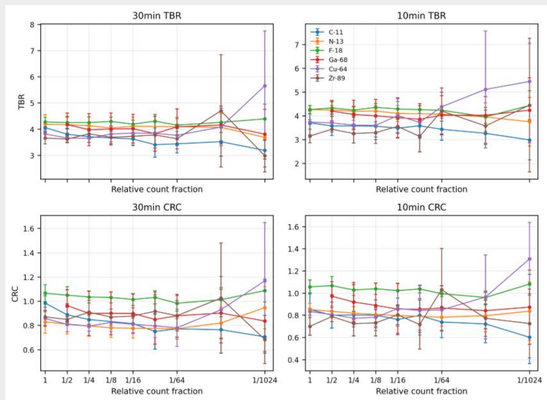

Figure 4A. Absolute TBR and CRC across radionuclides, acquisition durations, and half-life intervals.

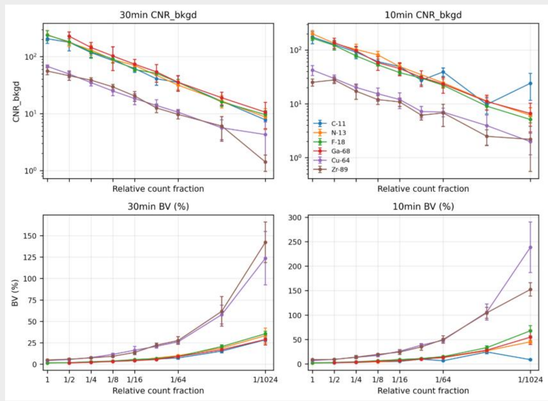

Figure 4B. Absolute CNR and BV% across radiotracers, acquisition durations, and half-life intervals.

DISCUSSION

- Delayed imaging is feasible but tracer- and size-dependent.
  - F-18 clearly enables the most forgiving delayed strategy, including for pediatrics.
  - Ga-68 is acceptable for ≥13–22 mm with moderate delay; small spheres remain range-limited.
  - C-11 or N-13 windows must be early due to short half-lives; delays erode DI/CNR rapidly.
  - Cu-64 offers a long window but needs time (or dose) to preserve DI.
- Quantitation vs. dose trade-offs are manageable with tailored windows.
  - For pediatrics, optimal balance is tracer- and size-specific; delaying too far without compensating time raises BV% and reduces diagnostic certainty
- Acquisition length is the key lever once dose is constrained.
- Late delay windows can be recaptured by lengthening acquisition or using advanced recon.
- Small lesions remain the limiting case; small-lesion performance cannot be inferred from CNR or CRC alone, especially for high-positron-energy radionuclides such as Ga-68
- The convergence of CNR and BV%-based thresholds provides a quantitative basis for describing the transition from contrast-preserved to noise-limited delayed OSEM imaging
  - suggests that delayed-image feasibility should be evaluated using detectability endpoints rather than TBR or CRC alone

CONCLUSIONS

Delayed OSEM PET imaging on the uMI Panorama GS LAFOV/total-body PET/CT scanner preserves mean contrast metrics over moderate count reductions.

CNR and BV% are therefore more appropriate primary endpoints for delayed-image feasibility than TBR or CRC alone.

Measured NECR retention provides a scanner-specific predictor of noise-sensitive degradation, while sphere-level CNR, BV%, CRC, and size-specific threshold analyses remain necessary for task-based interpretation.

This demonstrates the feasibility of extended imaging with quantitative accuracy preservation.

REFERENCES

1. Spencer BA, Berg E, Schmall JP, Omidvari N, Leung EK, Abdelhafez YG, Tang S, Deng Z, Dong Y, Lv Y et al: Performance Evaluation of the uEXPLORER Total-Body PET/CT Scanner Based on NEMA NU 2-2018 with Additional Tests to Characterize PET Scanners with a Long Axial Field of View. J Nucl Med 2021, 62(6):861–870.
2. Zhang H, Ren C, Liu Y, Yan X, Liu M, Hao Z, Xing H, Huo L: Performance Characteristics of a New Generation 148-cm Axial Field-of-View uMI Panorama GS PET/CT System with Extended NEMA NU 2-2018 and EARL Standards. J Nucl Med 2024, 65(12):1974–1982.

St. Jude - Confidential
© Poster Template by Genigraphics® 1.800.790.4001 www.genigraphics.com