2026 JULY 19–22 VANCOUVER, BC
JOINT AAPM | COMP MEETING

Commissioning of Scalp-Sparing Rotational Total Skin Electron Therapy (TSET)

Tianzhe Li[1,2], Andrew Fanning[1], Bridget Melke[1], Ryan Brunkhorst[1], Brett Thomas[2], Allen Pusek[2], Kimberly Wilson[2], Diane Schott[1,2], Charles Enke[1,2], Kyle J. Gallagher[1,2]
[1]University of Nebraska Medical Center, [2]Nebraska Medicine, Omaha, NE

INTRODUCTION

Mycosis fungoides (MF) is the most common primary cutaneous T-cell lymphoma, characterized by malignant CD4-positive T lymphocytes infiltrating the skin. It typically progresses from patches and plaques to tumor. Advanced cases of MF typically involve lymph nodes or visceral organs[1]. Treatment is stage-dependent and includes topical corticosteroids, phototherapy and systemic agents. Due to the high radiosensitivity of MF, localized diseases are effectively treated with electron beam radiotherapy, while extensive skin involvement is managed with total skin electron therapy (TSET), which provides excellent local control, symptom relief, and minimal dose to underlying organs. Conventional regimens of TSET deliver approximately 30–36 Gy over 8–10 weeks, whereas low-dose TSET (10–12 Gy) has emerged as an effective option with reduced toxicity and the need for salvage treatment.

Alopecia is one of the most common adverse effects of rotational total skin electron therapy (TSET), often causing significant psychological and social distress, particularly in patients whose personal or professional circumstances place great importance in hair preservation. Temporary alopecia generally occurs after radiation doses of approximately 2–3 Gy, whereas permanent alopecia becomes increasingly likely at cumulative doses exceeding 5-7 Gy. Hair loss is one of the most common toxicities of total skin electron therapy (TSET) for mycosis fungoides, with virtually all patients (approaching 100%) receiving conventional-dose TSET (30–36 Gy) experiencing temporary scalp alopecia during treatment.

Depending on the location of the disease, some patients may be candidates for scalp-sparing TSET. We herein present the commissioning of a modified-TSET setup with added shielding using lead sheets and a lead-covered helmet that was shown to effectively shield the scalp area to prevent significant hair loss.

A B

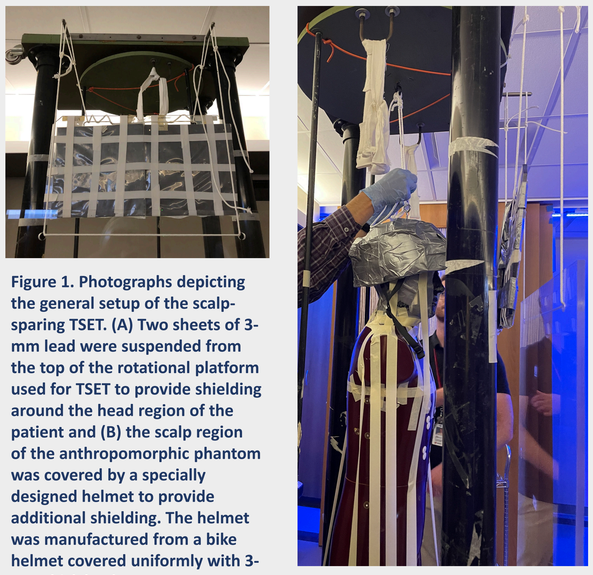

Figure 1. Photographs depicting the general setup of the scalp-sparing TSET. (A) Two sheets of 3-mm lead were suspended from the top of the rotational platform used for TSET to provide shielding around the head region of the patient and (B) the scalp region of the anthropomorphic phantom was covered by a specially designed helmet to provide additional shielding. The helmet was manufactured from a bike helmet covered uniformly with 3-mm thick lead.

METHODS AND MATERIALS

The TSET setup was modified to shield the head region of patients using two sheets of 3-mm lead suspended from the top of the rotational treatment platform (Fig 1A). Additionally, a lead helmet specifically for shielding the scalp region was fabricated by uniformly covering a helmet with 3-mm lead (Fig 1B).

To test the shielding of the lead helmet, radiochromic films were wrapped inside the helmet to detect potential locations for insufficient shielding while one fraction of 200 cGy total skin electron therapy was delivered to an anthropomorphic phantom.

Additionally, an end-to-end test was performed using the same anthropomorphic phantom during the scalp-sparing TSET. Thermoluminescence dosimeters (TLDs) were placed at 13 locations on the phantom for dose validation during the scalp-sparing TSET. To test the effectiveness of the lead helmet and the additional shielding at the head region, additional setup with the anthropomorphic phantom was performed using (1) only the lead sheets for shielding without the lead helmet and (2) no lead sheets or the lead helmet, with TLDs placed at 5 locations for each testing scenario. The readings from TLD measurements were compared among the three setups to quantify the reduction in scalp dose while verifying that the prescribed dose to the remaining treatment regions was maintained.

Table 1 and Figure 3. Results of dose validation with the anthropomorphic phantom and TLDs at 5 representative anatomical locations

Locations	No Pb Sheets, No Helmet (cGy)	Pb Sheets Only (cGy)	Pb Sheets + Helmet (cGy)
Forehead	213.7	32.9 ↓	23.7 ↓
Back of Head	213.1	49.3 ↓	**5.5 ↓↓**
Vertex	148.8	31.5 ↓	**2.3 ↓↓**
Mid Back	192.5	167.0 --	175.8 --
Umbilicus	215.2	182.0 --	188.9 --

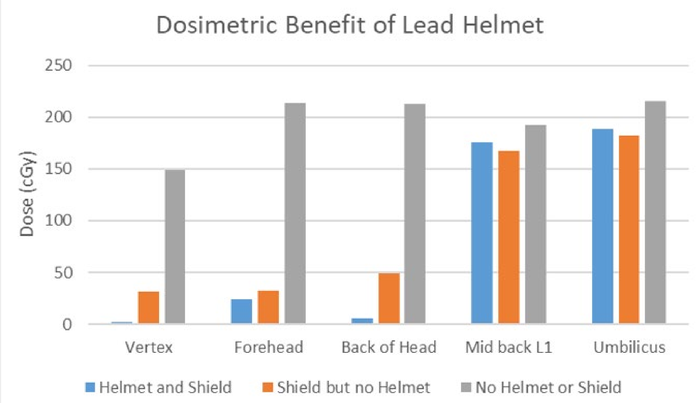

RESULTS AND DISCUSSION

Pieces and stripes of films placed inside the lead helmet were visually inspected after 200 cGy of total skin electron therapy was delivered to the anthropomorphic phantom wearing the helmet. The films have shown no obvious darkening in colors (Fig. 2), and this result confirms the shielding integrity of the lead helmet.

Readings from TLD chips placed at 5 representative anatomical locations on the anthropomorphic phantom irradiated with (1) no scalp-sparing TSET setup, (2) scalp-sparing TSET setup with only lead sheets and (3) scalp-sparing TSET setup with both lead sheets and lead helmet are presented in Table 1 and Figure 3. TLD measurements of the anthropomorphic phantom using the scalp-sparing TSET setup revealed significant dose reduction to the scalp area of the phantom with the greatest sparing occurring when both the helmet and the lead sheets were implemented. This setup reduced the dose by 98.5% for vertex, 88.9% for forehead and 97.4% for back of head. The special design did not significantly affect the dose for other areas of the body intended for treatment.



Figure 2. Radiochromic films placed inside of the lead helmet demonstrate no obvious or significant structural gaps, which can potentially lead to dosimetric hotspots, between lead coverings.

CONCLUSIONS

We have commissioned and validated a new setup for aiming to shield radiation dose to scalp region during treatment for mycosis fungoides with total skin electron therapy. The scalp-sparing TSET setup with added lead shielding from lead sheets and helmet can significantly decrease absorbed dose in the scalp, i.e., up to 97%. The new TSET treatment setup can effectively reduce the occurrence and severity of alopecia and reduce psychological stress for patients with special social needs for physical appearance.

REFERENCES

1. Nashan, D., Faulhaber, D., Ständer, S., Luger, T.A. and Stadler, R., 2007. Mycosis fungoides: a dermatological masquerader. British Journal of Dermatology, 156(1), pp.1-10.
2. Jones, G.W., Kacinski, B.M., Wilson, L.D., Willemze, R., Spittle, M., Hohenberg, G., Handl-Zeller, L., Trautinger, F., Knobler, R. and EORTC Cutaneous Lymphoma Project Group, 2002. Total skin electron radiation in the management of mycosis fungoides: consensus of the European Organization for Research and Treatment of Cancer (EORTC) Cutaneous Lymphoma Project Group. Journal of the American Academy of Dermatology, 47(3), pp.364-370.

CONTACT

Tianzhe Li, PhD
University of Nebraska Medical Center
tili@unmc.edu

Kyle J. Gallagher, PhD
University of Nebraska Medical Center
kygallagher@unmc.edu

© Poster Template by Genigraphics® 1.800.790.4001 www.genigraphics.com