2026 JULY 19–22 VANCOUVER, BC
JOINT AAPM | COMP MEETING

Task-Efficient Modality Selection for Deep Learning–Based Pre-Operational Glioma Segmentation

Mahdieh Kazemimoghadam[1], Mingli Chen[1], Qingying Wang[1], Xuejun Gu[2], and Weiguo Lu[1]*

[1]Department of Radiation Oncology, The University of Texas Southwestern Medical Center, Dallas TX, 75390 United States of America, [2]Department of Radiation Oncology, Stanford University, Stanford, CA 94305, United States of America

ABSTRACT

Deep learning–based glioma segmentation models are typically developed assuming availability of the complete standard MRI protocol (T1, T1-weighted contrast-enhanced -T1ce, T2, and FLAIR). However, complete imaging may not always be available in routine clinical workflows [1]. This study systematically evaluates the contribution of individual MRI modalities and their combinations to determine the minimum imaging requirements for accurate segmentation of glioma subregions. Using the BraTS 2021 dataset, multiple 3D transformer-based nnU-Net models were trained with different single- and multi-modality input combinations and evaluated using standard segmentation metrics. The findings provide insight into modality selection for efficient and clinically practical AI-based glioma segmentation.

CONTACT
Weiguo.lu@UTSouthwestern.edu

INTRODUCTION

Deep learning–based glioma segmentation models are commonly developed assuming availability of the complete standard MRI protocol (T1, T1-weighted contrast-enhanced [T1ce], T2, and FLAIR). However, complete MRI acquisitions are not always feasible in clinical practice, particularly in time-constrained workflows such as adaptive radiotherapy. The contribution of individual MRI modalities to the segmentation of specific glioma subregions has not been systematically quantified, leaving uncertainty regarding the minimum imaging required for reliable AI-based segmentation [2].

Objective: To systematically evaluate the contribution of individual MRI modalities and their combinations for segmentation of edema (ED), enhancing tumor (ET), and necrotic core (NCR), and identify the minimum MRI protocol required for accurate glioma subregion segmentation.

METHODS AND MATERIALS

This study utilizes the BraTS 2021 dataset, which includes multi-institutional brain MRI scans of adult glioma patients with four structural modalities: T1, T1ce, T2, and FLAIR, along with expert voxel-wise annotations for edema (ED), enhancing tumor (ET), and necrotic core (NCR). A total of 1,251 cases with complete imaging and labels were included, with 210 cases reserved as an independent test set and the remaining cases used for training and validation (70% and 30% respectively). Eight 3D transformer-based nnU-Net models were trained using different combinations of MRI modalities as input channels. Performance was evaluated on the held-out test set using Dice similarity coefficient (DSC), enabling direct assessment of segmentation accuracy as a function of modality selection.

RESULTS

Quantitative evaluation revealed strong subregion-specific dependence on MRI modality selection (Figure 1). For edema segmentation, FLAIR-only input achieved the highest Dice (0.81±0.13) among all single-modality models. Among multi-modality models, the T1ce + FLAIR combination achieved a high DSC of 0.86±0.11, closely matching the performance of models incorporating additional modalities, including T1 + T1ce + FLAIR and the complete four-modality configuration (T1, T1ce, T2, and FLAIR), which yielded no meaningful improvement. For enhancing tumor and necrotic core segmentation, T1ce was the dominant modality (0.83±0.23 and 0.77±0.29 respectively), yielding the highest single-modality Dice scores. Importantly, multi-modality inputs incorporating additional sequences beyond T1ce and FLAIR did not result in meaningful improvements in segmentation accuracy.

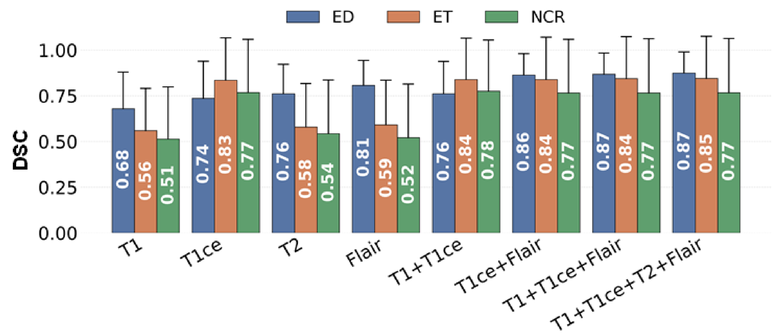

Figure 1. DSC for pre-operational glioma segmentation across MRI modality combinations. Error bars represent standard deviation. FLAIR provides the strongest single-modality performance for edema, while T1ce dominates enhancing tumor and necrotic core segmentation. Inclusion of additional modalities beyond T1ce and FLAIR yields minimal performance gains.

Figure 2 presents representative cases segmented using single-modality (T1ce, FLAIR) and multimodal (T1ce + FLAIR) deep learning models. The model trained on T1ce accurately delineates the enhancing tumor and necrotic core, while the FLAIR-only model yields clear and spatially coherent segmentation of edema. The multimodal T1ce + FLAIR model integrates these complementary contrasts, producing accurate and anatomically consistent segmentation across all three tumor subregions, with preserved spatial hierarchy between necrosis, enhancing tumor, and surrounding edema.

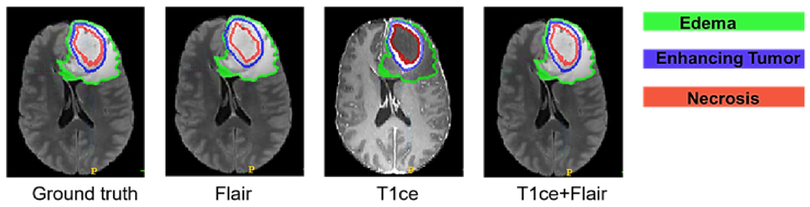

Figure 2. Representative cases segmented using single-modality (T1ce, FLAIR) and multimodal (T1ce + FLAIR) deep learning models. Edema (green) is well delineated using FLAIR-based models, while enhancing tumor (blue) and necrotic core (red) are more accurately segmented on the model trained on T1ce. The model trained on combined T1ce and FLAIR yields optimal segmentation performance across all tumor subregions.

DISCUSSION AND CONCLUSIONS

Accurate deep learning–based glioma subregion segmentation does not require fully multimodal MRI. The combination of T1ce and FLAIR is sufficient for robust segmentation of glioma supporting task-efficient modality selection and clinically realistic AI deployment.

REFERENCES

[1] Rasool, Novsheena, and Javaid Iqbal Bhat. "A critical review on segmentation of glioma brain tumor and prediction of overall survival." *Archives of Computational Methods in Engineering* 32.3 (2025): 1525-1569.
[2] Pemberton, Hugh G., et al. "Multi-class glioma segmentation on real-world data with missing MRI sequences: comparison of three deep learning algorithms." *Scientific reports* 13.1 (2023): 18911.

© Poster Template by Genigraphics® 1.800.790.4001 www.genigraphics.com