2026 JULY 19–22 VANCOUVER, BC
JOINT AAPM | COMP MEETING

Enhanced Soft Tissue Contrast in Neonatal Brain Imaging Using Deep Silicon Photon Counting CT (dSi-PCCT): A Custom Phantom

Zhye Yin, PhD[1]; Lusik Cherkezyan, PhD[1]; Mehgan Yue, MS[1]; Brian Nett, PhD[1]; Amir Pourmorteza, PhD[2]
[1]GE HealthCare, [2]Emory University

ABSTRACT

Purpose: To evaluate the low-contrast performance of deep silicon photon-counting CT (dSi-PCCT) for neonatal brain imaging using a custom phantom designed to replicate clinically relevant neonatal skull and soft-tissue attenuation.

Methods: A custom neonatal brain phantom containing tissue-equivalent inserts simulating cerebrospinal fluid (CSF) and neonatal brain tissue (10–20 HU contrast) was scanned at matched radiation dose ($CTDI_{vol}$ = 18 mGy) on a dSi-PCCT system and a conventional energy-integrating detector CT (EID CT) system. Contrast-to-noise ratio (CNR) between the CSF and brain tissue surrogates was measured.

Results: At matched radiation dose, dSi-PCCT demonstrated 15.5% and 24.0% higher CNR than EID CT acquired at 80 kVp and 100 kVp, respectively. Improved CNR was achieved despite the dSi-PCCT acquisition being performed at 120 kVp.

Conclusion: The custom neonatal brain phantom enabled clinically relevant assessment of pediatric brain CT image quality. dSi-PCCT provided superior low-contrast performance compared with conventional EID CT, highlighting its potential to improve visualization of subtle neonatal brain structures and increase diagnostic confidence.

INTRODUCTION

Neonatal brain CT requires visualization of subtle attenuation differences (10–20 HU) between cerebrospinal fluid (CSF) and immature brain tissue[1]. Maintaining sufficient contrast-to-noise ratio (CNR) is particularly challenging because pediatric imaging requires low radiation dose while skull attenuation further degrades image quality. Conventional image quality phantoms are not designed to represent neonatal anatomy or these clinically relevant soft-tissue contrasts[2].

To address this need, a custom neonatal brain phantom was developed to replicate realistic neonatal skull thickness and clinically relevant soft-tissue attenuation. Using this phantom, the present study quantitatively compared the low-contrast performance of deep silicon photon-counting CT (dSi-PCCT) and conventional energy-integrating detector CT (EID CT) under matched pediatric imaging conditions.

METHODS AND MATERIALS

A custom neonatal brain phantom was developed to replicate clinically relevant neonatal skull thickness and soft-tissue attenuation, shown in Figure 1. The phantom consisted of a skull-mimicking outer shell surrounding a water-filled central compartment containing tissue-equivalent inserts. NaCl solutions were used to simulate cerebrospinal fluid (CSF) and neonatal brain tissue with attenuation differences of approximately 10–20 HU.

The phantom was scanned at a matched radiation dose ($CTDI_{vol}$ = 18 mGy) on a deep silicon photon-counting CT (dSi-PCCT, Photonova Spectra, GE HealthCare) system and an energy-integrating detector CT (EID CT, Revolution Apex, GE Healthcare) system. dSi-PCCT images were acquired at 120 kVp and reconstructed as 65-keV virtual monoenergetic images, while EID CT images were acquired at 80 and 100 kVp. Images from both systems were reconstructed using matched soft-tissue kernels(Stnd for EID CT and HD Stnd for dSi-PCCT), medium-strength deep-learning denoising (DL-M), a 1.25-mm slice thickness, and a 512 × 512 matrix.

Contrast-to-noise ratio (CNR) between the CSF and brain tissue surrogate inserts was measured and compared across the three imaging conditions.

RESULTS

Representative neonatal brain phantom images acquired on EID CT (80 and 100 kVp) and dSi-PCCT (65 keV) at matched radiation dose are shown in Figure 2. The dSi-PCCT images demonstrated the highest contrast-to-noise ratio (CNR) among all imaging conditions.

Quantitative CNR measurements showed improvements of 15.5% and 24.0% relative to EID CT at 80 kVp and 100 kVp, respectively, shown in Table 1. Notably, these improvements were achieved even though dSi-PCCT acquired data at 120 kVp, while the EID CT images were acquired at lower tube potentials that are conventionally expected to provide higher soft-tissue contrast.

The improved CNR enabled clearer separation between the cerebrospinal fluid (CSF) and neonatal brain tissue surrogate inserts, representing attenuation differences of only 10–20 HU. The measured CNR exceeded the predefined acceptance criterion for both EID CT comparisons, demonstrating robust low-contrast performance under clinically relevant pediatric imaging conditions.



Figure 1. Illustration of the custom neonatal brain phantom used to evaluate CT image quality in pediatric brain imaging. (B) Non-contrast head scout image from a 10-month-old patient. (A) Scout image acquired from the phantom, demonstrating the range of skull-mimicking concrete thicknesses. (C) Photograph of the phantom's insert without the outer cylinder (inverted up-down), showing vials with relevant solutions inserted into designated slots and submerged in DI water. (D) Photograph of the assembled phantom with the outer cylinder with the bone-mimicking material, with ends of the vials visible at the top. The thickness of the cylinders' walls changes in the vertical direction such that different bone thickness can be modeled for axial CT images. (E) Axial CT image pointing to the vials used in this evaluation (WW/WL = 100/30).

Table 1. . Results of mean and standard deviation measurements inside selected ROIs corresponding to EID CT 80kVp, 100 kVp, and dSi-PCCT 65keV images from scan acquisitions at matched radiation dose.

CT System	1 mL NaCl (~CSF)		3 mL NaCl (~brain tissue)		CNR
	Mean	SD	Mean	SD	
EID CT 80kVp	8.4	4.6	25.1	4.5	3.63
EID CT 100kVp	6.8	4.7	22.7	4.8	3.38
dSi-PCCT 120kVp	6.6	3.1	19.6	4.2	4.19
% Difference between dSi-PCCT and 80kVp EID CT					15.5%
% Difference between dSi-PCCT and 100kVp EID CT					24.0%

DISCUSSION

This custom phantom provides a clinically relevant platform for evaluating neonatal brain CT image quality by replicating realistic neonatal skull attenuation and clinically relevant soft-tissue contrast between CSF and brain tissue.

Although low-kVp imaging is commonly used to improve soft-tissue contrast in pediatric CT, dSi-PCCT demonstrated higher CNR than both 80- and 100-kVp EID CT at matched radiation dose. The improvement is likely attributable to the enhanced spectral information provided by its 8-energy-bin detector design, resulting in improved contrast preservation while maintaining low image noise.

Consistent with previous studies demonstrating the advantages of PCCT for neuroimaging and brain image quality assessment[3], these findings suggest that dSi-PCCT may improve visualization of subtle neonatal intracranial abnormalities, increase diagnostic confidence, and potentially reduce repeat imaging.

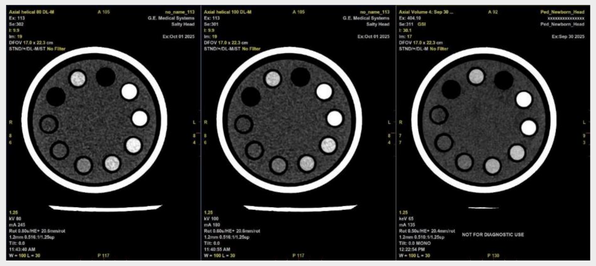

Figure 2. Axial CT sections used for CNR assessment for EID CT 80kVp (left), 100 kVp (center), and dSi-PCCT 65keV (right).

CONCLUSIONS

A clinically realistic neonatal brain phantom was developed for quantitative evaluation of pediatric brain CT image quality. At matched radiation dose, dSi-PCCT demonstrated 15.5% and 24.0% higher CNR than 80- and 100-kVp EID CT, respectively. dSi-PCCT exceeded the predefined image quality acceptance criterion under clinically relevant neonatal imaging conditions. These results demonstrate the potential of dSi-PCCT to improve low-contrast detectability and diagnostic confidence in neonatal neuroimaging.

REFERENCES

1. H. Sekkat, A. Khallouqi, O. El Rhazouani, et al., "Study of attenuation characteristics for novel neonatal head phantom in diagnostic radiology using Monte Carlo simulations and experiments," Biomed. Phys. Eng. Express 11, 025031 (2025).
2. H. Sekkat, A. Khallouqi, Y. Madkouri, et al., "Towards novel methods of dosimetry in pediatric and neonatal head computed tomography: Comparative study using two novel and cost effective fabricated in-house phantoms," Phys. Med. 145, 105789 (2026)
3. A. Pourmorteza, R. Symons, D. S. Reich, et al., "Photon-counting CT of the brain: In vivo human results and image-quality assessment," AJNR Am. J. Neuroradiol. 38, 2257–2263 (2017).

CONTACT

Zhye Yin
GE HealthCare, Waukesha, WI 53188
Zhye.yin@gehealthcare.com

© Poster Template by Genigraphics® 1.800.790.4001 www.genigraphics.com