2026 JULY 19–22 VANCOUVER, BC
JOINT AAPM | COMP MEETING

Minimizing motion in SPECT-CT images from MAA Mapping and Y-90 post injection

Kenneth C. Chu, PhD, Georgios Kalantzis, PhD, Frank T. Godlewski, MBA, Debra Linzer, MD, Adam Zybulewski, MD, Andre Krauthamer, MD , Nicolas Kuritzky, MD
Mount Sinai Medical Center, Miami Beach, FL 33140

Mount Sinai
MEDICAL CENTER
Braman Comprehensive Cancer Center

INTRODUCTION

Purpose:
The NRC reported that between 2015 to 2024 nearly 50% of Medical Events were Y-90 related. (As our institution started to analyze SPECT/CT images in 3D to measure the lung shunt from 99mTc-MAA mapping of liver tumors, we found that a large percentage of the images were clearly mis-registered by up to 3cm). This misalignment was attributed to patient motion between the fast CT scan (0.5 minutes) and the slower SPECT scan (20 minutes). We speculated that a small amount of these NRC reported events may be caused by this mis-registration.

Although certain misregistered scans can be manually corrected using special fusion software, this is prone to operator error. The purpose of this research was to eliminate any patient motion.

METHODS AND MATERIALS

Patients undergoing MMA mapping or post Y-90 treatment were imaged on a GE Discovery NM/CT 670 v1.003. Post processing and motion correction of the raw data was done on the Xeleris 3 workstation. These images were then exported to our MIM system v7.4.1 software, for 3D analysis.

When viewed in 3D with the MIM software, it was obvious there was misalignment between the SPECT/CT images. The MIM software allowed us to manually correct the registration.

RESULTS

Requiring the physicist attend an actual SPECT/CT session, they noticed that the default CT Protocol announced "***Breathe in, hold your breath***". This has continued for several years before it was noticed.

DISCUSSION

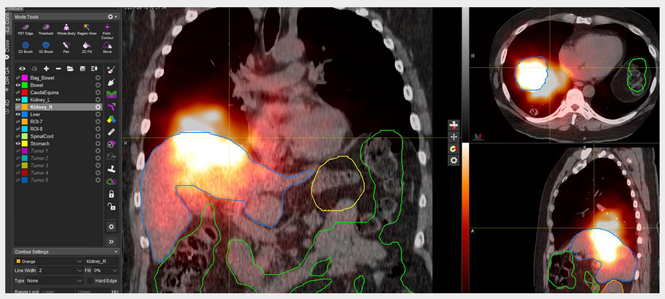

Figure 1 above: Post Y-90 injection: The original CT protocol set by vendor announced, "Breathe In, hold your breath", and the SPECT and CT appear misregistered. At first appearance, one might think that the lung dose was quite high.

Figure 2 below: To prove our hypothesis, the same patient also had a repeat CT with the auto announcement turned off (and patient was verbally told to just breathe normally). In this image set, NO corrections were required, as the SPECT and CT appear aligned.
Hence, we can conclude by saying that the announcement of "Breathe In, hold your breath" displaces the thoracic organs. Note: They are not just displaced but also DEFORMED due to the increase in lung volume.

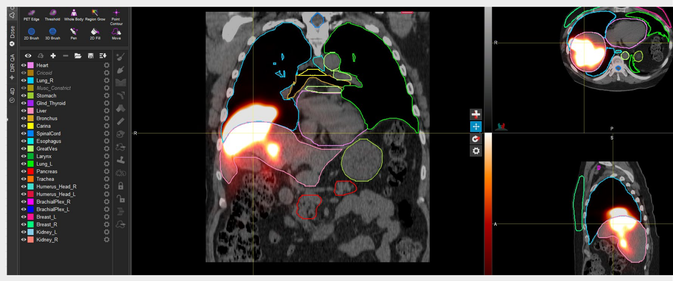

Figure 3 above: Same Patient: the MAA Mapping performed one week earlier using the CT protocol to telling the Patient to "Breathe In, hold your breath" results in a SPECT image that is clearly misregistered compared to the CT images, as the Shape of the MAA SPECT looks like it is in the liver but significantly displaced in the coronal image. Without any rigid registration corrections, the lung shunt would have the exceeded 20% level, and the Y-90 procedure cannot be performed on this patient.

Figure 4 above : Correcting the MAA Mapping: The MIM software allows us to manually correct the mis-alignment by having the SPECT image moved rigidly 26 mm inferiorly, 5 mm Posteriorly, and 2 mm to the left. Although the images look like they're aligned, drawing of the target is only approximate and calculation the lung shunt volume will not be very accurate due to deformation. The lung volume is over expanded due to the CT announcement of "Breathe In, hold your breath".

CONCLUSIONS

Requiring the physicist attend an actual SPECT/CT session, they noticed that the default CT Protocol the announced "Breathe in, hold your breath". This has continued for several years before it was noticed.

We have analyzed 16 patients before and 11 patients after stopping the auto announcement and found that the required post correction was reduced in number by 62% and 50% magnitude.

More patient data is needed to validate these results.

CONTACT

Kenneth Chu, PhD, P.Eng,
Chief Physicist
Mount Sinai Medical Center
Radiation Oncology,
Braman Comprehensive
Cancer Center
4310 Alton Road
Miami Beach, FL 33140

Kenneth.Chu@MSMC.COM

305-674-2121 ext 57440

ACKNOWLEDGEMENTS

This work was supported by a grant from Florida Cancer Innovation Fund

© Poster Template by Genigraphics® 1.800.790.4001 www.genigraphics.com