Assessing the dosimetric accuracy and time savings of MR-based deep learning auto-segmentation implemented in a gynecological high dose rate (HDR) brachytherapy clinical setting

2026 JULY 19–22 VANCOUVER, BC
JOINT AAPM | COMP MEETING

Renae Conlin, PhD[1], Asma Amjad, PhD[1], Natalya Morrow, PhD[1], Rhonda Geoffrey, PhD[1], Jason Rownd, MS[1], Philip Prior, PhD[1], Beth Erickson, MD[1]
[1]Radiation Oncology, Froedtert and Medical College of Wisconsin

Froedtert & Medical College of Wisconsin

ABSTRACT

Purpose: Gynecological high dose rate (HDR) brachytherapy patients receiving treatment for cervical cancers are under anesthesia during planning and treatment. Minimizing planning time without compromising safety and effectiveness would improve patient care, improve planner workload, and reduce the burden on hospital resources. In this study, we assess the time savings and accuracy of a deep learning auto-segmentation (DLAS) model when applied to daily MRI for clinical planning.

Methods: A single-institution DLAS model trained on 61 T2 Space MR images with U-net, and tandem and ring (TR) applicator in situ was implemented in the clinic. This model was used to contour organs at risk (OARs), the bladder, rectum, sigmoid, and small bowel, on daily MRIs from eight patients (with Tandem and Cylinder (TC), Advanced Gynecological Applicator (AGA), and AGA with needles cervical brachytherapy applicators in situ). The DLAS and edited DLAS contours (e-DLAS) used for planning were compared using contour volumes and dosimetric criteria (D0.1cc, D1.0cc, and D2.0cc). Editing times of the e-DLAS were compared with clinical contouring times acquired prior to MR-DLAS implementation.

Results: Mean volume differences (DLAS – e-DLAS volume), for bladder, rectum, sigmoid, and small bowel were (-2.31±12.77, -1.69±11.74, -19.38±26.19, -7.87±48.64cc), respectively. Mean dosimetric differences in bladder, rectum, sigmoid, and small bowel for D0.1cc (-8.43±9.06, 16.93±47.16, -1.16±88.49, 13.19±151.11cGy), D1.0cc (-6.82±9.65, 9.58±35.60, -14.44±61.11, 26.11±104.19cGy), and D2.0cc (-23.94±51.64, 2.78±28.68, -30.04±66.77, 25.74±89.19cGy), respectively. Segmentation time was <1 minute for all cases. The average time for e-DLAS contours was 30.1±12.5 minutes, with a range of 13.5–47.5, versus 52.5 minutes and a range of 15–110 before the MR-DLAS implementation.

Conclusion: This study demonstrates the potential of MR-DLAS for gynecological HDR brachytherapy planning. While the introduction of MR-DLAS expedited and standardized the contouring part of the planning process, it was limited by atypical anatomy, as seen with longer editing times.

CONTACT

Renae Conlin, PhD
Medical Physics Resident
reconlin@mcw.edu

INTRODUCTION

MR imaging is ideal for daily high-risk clinical target volume (HR-CTV) delineation in high dose rate (HDR) gynecological brachytherapy treatment planning because of its excellent soft-tissue contrast. There are very few auto-contouring solutions available for MRI in the female pelvis[1]. This limitation can result in prolonged contouring times for the daily anatomy while the patient is under anesthesia. In-house trained deep learning auto-segmentation (DLAS) models may provide a viable solution.

This study evaluates the effectiveness of integrating DLAS into the clinical workflow for gynecological HDR brachytherapy at our institution.

METHODS AND MATERIALS

- Single-institution DLAS model
  - U-net
  - 61 T2-space MR images
  - Tandem and ring (TR) applicator in situ
- Eight patients with cervical brachytherapy applicators in situ
  - Tandem and Cylinder (TC)
  - Advanced Gynecological Applicator (AGA)
  - AGA with needles
- 4 organs at risk (OARs) contoured on daily MRIs
  - Bladder
  - Rectum
  - Sigmoid
  - Small bowel
- DLAS and edited DLAS contours (e-DLAS) used for planning were compared
  - Mean volume differences (DLAS – e-DLAS volume)
  - Dosimetric criteria (D0.1cc, D1.0cc, and D2.0cc)
- Editing times of the e-DLAS were compared with clinical contouring times acquired prior to MR-DLAS implementation

RESULTS

- DLAS tended to under-contour the bladder, rectum, sigmoid, and small bowel
- Good agreement in the dosimetric metrics, D0.1cc, D1.0cc, and D2.0cc, for bladder and rectum
- Mean volume differences (DLAS – e-DLAS volume) and mean dosimetric differences for bladder, rectum, sigmoid, and small bowel are shown in Table 1
- Average time for e-DLAS contours was 30.1±12.5 minutes, with a range of 13.5–47.5, versus 52.5 minutes and a range of 15–110 before the MR-DLAS implementation. Editing times are seen in Table 3

Table 1: Mean differences in volume and dosimetric criteria between DLAS and e-DLAS, where Δ = DLAS – e-DLAS.

OAR	$\overline{\Delta volume}$ (cc)	$\overline{\Delta dose}$ D0.1cc (cGy)	$\overline{\Delta dose}$ D1.0cc (cGy)	$\overline{\Delta dose}$ D2.0cc (cGy)
Bladder	-2.31±12.77	-8.43±9.06	-6.82±9.65	-23.94±51.64
Rectum	-1.69±11.74	16.93±47.16	9.58±35.60	2.78±28.68
Sigmoid	-19.38±26.19	-1.16±88.49	-14.44±61.11	-30.04±66.77
Small Bowel	-7.87±48.64	13.19±151.11	26.11±104.19	25.74±89.19

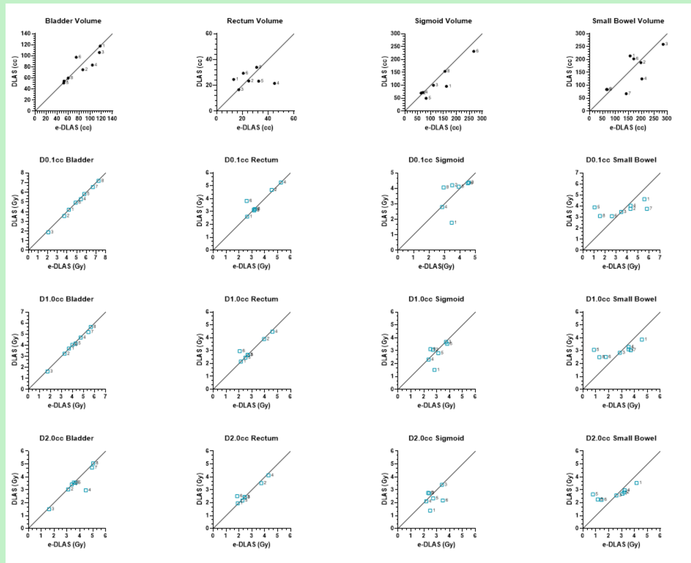

Figure 1. DLAS vs e-DLAS volume and volumetric dose criteria. The line of identity is shown on each graph

Table 2: DLAS and e-DLAS are shown on the same axial slice, with isodose lines, for patients 6 and 8.

	DLAS	e-DLAS
Patient 6. The DLAS rectum (brown) is superior and closer to the high-dose cloud than the e-DLAS. e-DLAS shows sigmoid (green).		
Patient 8. Benign ovarian cyst contoured as sigmoid (green) by DLAS (arrows) and is closer to the high dose cloud than e-DLAS, thus explaining the higher D0.1cc in the DLAS compared to e-DLAS.	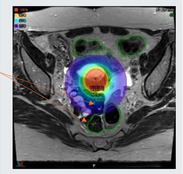	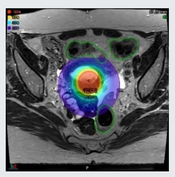

Table 3: Editing times for DLAS

Patient	Editing time (min)	Comments
1	45.5	Challenging small bowel anatomy
2	21.0	
3	23.9	
4	47.5	Motion artifacts in the small bowel and sigmoid
5	13.5	
6	23.5	Large pelvic cyst
7	26.0	No rectum
8	40.0	Large ovarian cysts

DISCUSSION

Figure 1 shows that while the DLAS tended to under contour the bladder, rectum, sigmoid colon, and small bowel, there was strong agreement in dosimetric metrics D0.1cc, D1.0cc, and D2.0cc for the bladder and rectum. The negative mean contour volume differences and lower standard deviations for these organs, as noted in Table 1, indicate good agreement between the DLAS and e-DLAS contours. The higher standard deviation for the sigmoid colon and small bowel suggests that additional contour editing may be required for these organs in certain patients.

The outlier data point for the D0.1cc, D1.0cc, and D2.0cc rectum measurements in Figure 1 shows that DLAS is closer to the HR-CTV, resulting in hotter dosimetry in the rectum and cooler in the sigmoid, as noted in Table 2. Patients 6 and 8 had atypical anatomy with large pelvic cysts, some contoured as small bowel and sigmoid, with an example for patient 8 shown in Table 2.

In the timing study, e-DLAS were created by brachytherapy physicists, with editing times shown in Table 3. Patients 1, 4, and 8 experienced longer editing times due to complex small bowel and sigmoid contouring influenced by anatomy or motion artifacts. The average time savings with MR-DLAS is approximately 22.4 minutes; actual savings may be conservative since editing occurs alongside the physicist and physician. Time savings were consistent for bladder and rectum contouring, but variable for sigmoid and small bowel.

Figure 2 illustrates good agreement between DLAS and e-DLAS for the four organs at risk (OARs).

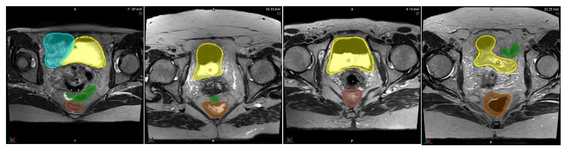

Figure 2. Images that show good agreement between DLAS (line) and e-DLAS (filled). Yellow, brown, green, and blue are bladder, rectum, sigmoid, and small bowel, respectively

CONCLUSIONS

This study demonstrates the potential of MR-DLAS for gynecological HDR brachytherapy planning. While the introduction of MR-DLAS expedited and standardized the contouring part of the planning process, it was limited by atypical anatomy, as seen with longer editing times.

References

1. Asma Amjad, et.al. PO0104: Advancing CT Based GYN HDR Brachytherapy with Automatic Deep Learning Based Segmentation Tool, Brachytherapy, Volume 23, Issue 6, Supplement, 2024, Pages S87-S88, ISSN 1538-4721, https://doi.org/10.1016/j.brachy.2024.08.126.

© Poster Template by Genigraphics® 1.800.790.4001 www.genigraphics.com